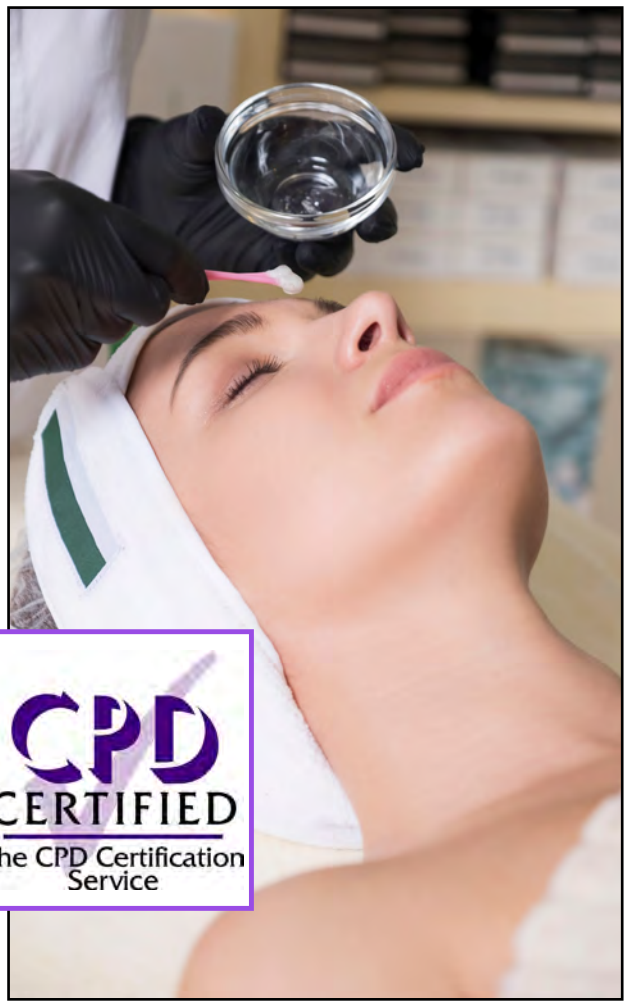

Anna Demianenko/Shutterstock

TIME TO RETHINK CHEMICAL PEELS

Professor Tony Chu (President of the Acne & Rosacea Association, Previous Lecturer and Lead Consultant Dermatologist at Imperial London, and Professor of Dermatological Oncology) explains how different chemical peel ingredients can effectively treat common facial skin concerns by utilising new technology, so they are much more than exfoliating devices.

Chemical peels have made somewhat of a comeback in the past few years. There used to be more concern amongst practitioners about the effects of harsh ingredients in the peels, leading many to err on the side of caution. Around the same time, a variety of lasers started to come on to the market and peels were seen as less favourable.

However, more recently, rather than being predominantly utilised for their exfoliating properties and influence on collagen matrix turnover, peels are being used to achieve significant results in common skin concerns.

There are many chemical agents available for skin peeling due to the advent of new 'carrier' systems, which can vary their impact from exfoliators to deep skin re-modellers, through to treatments for acne, rosacea, lines and wrinkles, pigmentation, and stretch marks.[1,2,3,4,5] Used properly, I believe they can have substantial effects comparable to lasers and radiofrequency, and are far less likely to cause post-inflammatory hyperpigmentation (PIH).

This article discusses the different types of peeling agents and the results that can be achieved.

Treating the skin with peeling agents

The newly developed carrier solutions take the acids and associated treatment ingredients (protected from degradation by the acid by the carrier solution) across the stratum corneum and deep into the skin before being released to target specific skin concerns.

It is recommended all peels are used in conjunction with creams, (pre, post and in between peel treatments), which contain the same ingredients as those held in the peels. The peels will therefore boost activity of the creams, but also will minimise post procedural risk of PIH or excessive erythema.[1,2,3,4,5]

Below are some case study examples of multiple skin conditions that patients may present with and the appropriate peel treatments:

Case study: Patient A

- Sun damage
- Dark and puffy under eye
- Reddening central area prone to rosacea
- Spots and acne

Patient A has sun damage on the forehead, is prone to reddening and has some intermittent or permanent redness/vascularity in the central portion of the face. She also has recurrent outbreaks of spots around the chin and has dark and puffy areas under the eye – a delicate area of skin that needs a different approach.

Mosaic peeling is the new buzz phrase for selecting the most appropriate peel for each area utilising specific solutions best suited to each of the above indications, rather than a 'cocktail' peel approach of multiple acids applied to all areas or utilising a generic single acid such as glycolic acid.

Both those offerings are a 'one size fits all' approach; its lazy technique and will deliver poorer outcomes and

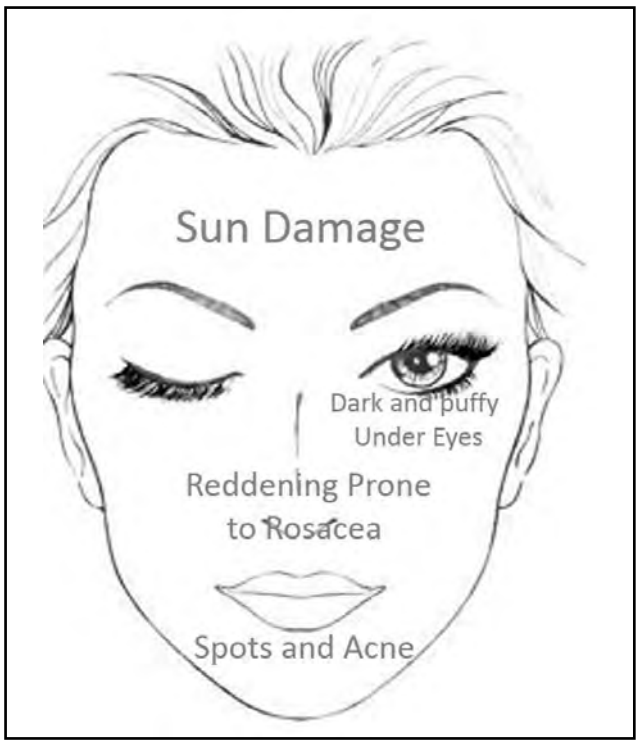

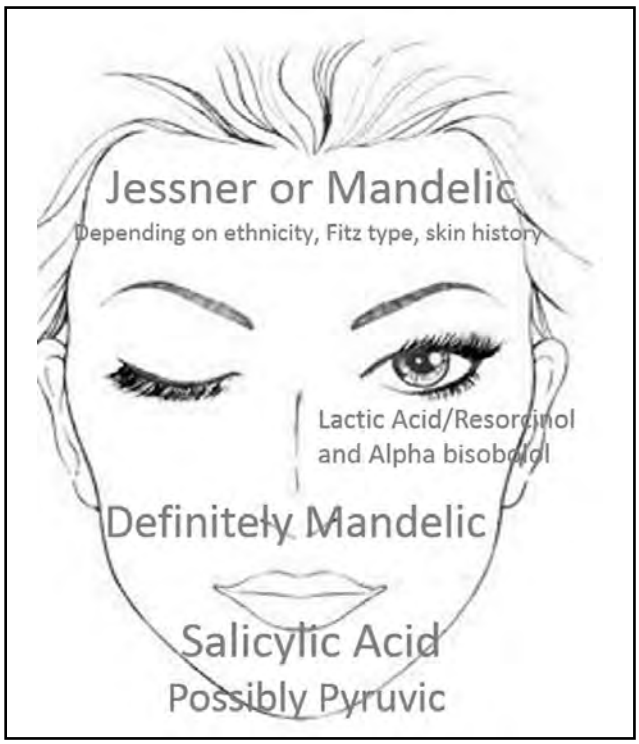

increase the risk of complications.

Glycolic acid is a general-purpose acid, it's not lipophilic, and I believe other acids have better properties for specific skin issues, such as above.

One might argue, if one had various skin issues in different areas of the face, that a 'cocktail' peel, i.e., a peel with multiple acid or peeling ingredients, may be ideal; but each acid in the cocktail will be applied to all areas of the face and some may have a negative effect on some of the skin issues mentioned, while being positive in others. The 'cocktail' combination can cause increased pigmentation on the forehead as well as exacerbating the central area and increasing erythema and redness.

The diagram above represents a preferred choice of peels for Patient A.

Please note that this is for a patient whereby we have assessed them for risk issues, such as skin ethnicity, dehydration and trans epidermal water loss (TEWL) issues and found them to be low risk.

40% mandelic acid is better for erythema control, 30% salicylic better for oil reduction, Jessner's (14% resorcinol, 20% lactic acid and 15% salicylic acid), is better for sun damage.

Glycolic would not be my choice for any of these.[9,10] However, in darker more reactive skin types one might use mandelic acid instead of the Jessner's. In either case, one would look to diminish complication risk utilising serums and creams which may reduce inflammatory issues such as hyperpigmentation or damage to vascular tissues. Also, the creams synergise with the peels to achieve the desired outcome and the creams deliver more than 50% of the result.

The unique feature of the carrier solutions is that the salicylic has three antibacterials and oil slowing ingredients also incorporated in the carrier matrix, which is delivered into the blocked hair follicle ducts. This peel is medically licensed for the treatment of comedogenic and inflammatory acne and resistant acne where in conjunction with the medically licensed creams containing the same antibacterials, anti-inflammatory and oil supressing ingredients resolved the symptoms of over 80% of GP referred resistant acne patients (defined as not resolved within 12 months) referred to the five teaching hospitals.

The mandelic is transported by the carrier into the dermis where it is released and activated and has a vasoconstrictive effect delivering improved vascular integrity, while the anti-inflammatories found in the rosacea creams are delivered with the mandelic to help control diffuse redness and increase flushing resistance, while also restricting VEGF from triggering excessive new capillary production. This peel is licensed for the treatment of vascular sub type 1 rosacea.

The Jessner's peel also uses carrier technology to release anti-inflammatories into the upper epidermis to minimise erythema while the lactic acid and resorcinol are delivered predominantly to the area either side of the dermal epidermal junction to act on slowing melanogenesis. A form of resorcinol and other ingredients are provided in the creams to continue to normalise melanin production between treatments.

This mosaic approach is slightly more complex and needs a little bit more planning, but it will be far more attractive. The unused peel solution can be resealed with a reversible cap, and the remaining solution can be used on the second and third peel in the course of treatment, 2 to 4 weeks apart.

Mandelic acid 40% is typically a 10-minute exposure where as Jessners and Salicylic are both five minutes exposure and then the salicylate powder that forms (deactivated salicylic acid) is just removed. In the case of the Jessner's, the lactic acid and resorcinol component is left in the skin to continue to work on the excess melanin production. This is termed extended exposure, but nothing is left on the surface of the skin.

Illustrations supplied by the author

ARA UK

What is the Acne and Rosacea Association UK?

The ARA UK, founded by Professor Tony Chu, aims to improve the management of Acne and Rosacea by providing the 6.5 million UK sufferers with Accredited Treatment and Advice Centres to form a patient referral network.

Who is Professor Chu?

Professor Tony Chu has over 43 years' experience in the research and treatment of Acne and Rosacea, as Professor of Dermatological Oncology, Previous Head of Dermatology and Senior Lecturer at Imperial College Hospitals, London, and President of the ARA UK.

Acne and Rosacea: The Facts

- 1 in 10 adults in the UK suffer from Rosacea, the equivalent of 5 million people in the UK
- 85% of people in the UK suffer from acne at some point in their lives, and 15% of the population have acne on any given day of the year

Sufferers that contact the ARA UK are referred to their nearest Acne and Rosacea Accredited Treatment Centre.

Become Accredited and these sufferers could be your patients.

Call – 0333 247 2413 | email – support@arauk.co.uk | visit – www.arauk.co.uk

So, at time zero the mandelic is applied to the central area of the face and at minute 5 the Jessner's and 30% salicylic acid are applied to the forehead and lower face respectfully. At minute 10 all three are removed with a remover wipe or saline dampened cotton pads. The mandelic can either be removed or neutralised.

Although you may see many patients with the exact same skin problems, it is not possible to treat everyone with the same solution. The patient's skin sensitivity, Fitzpatrick skin type, ethnicity, and the severity of photo damage and wrinkles, should all be taken into consideration.

The choice of agent will also vary depending on whether the patient has good skin moisture levels; for example, a high rate of TEWL (trans epidermal water loss) coupled with low hydration may indicate poor lipid density, and this may lead to a higher sensitivity to the remodelling agent and increase risk of adverse events such as erythema and PIH.

In this situation, I may revert to using a sequence of mandelic acid peels. The results may take longer to achieve but one would be mitigating for increased PIH risks.

Skin considerations

As mentioned, certain aspects should be taken into consideration before using any chemical peel.

Ethnicity

Patients with mixed race background, who, for example, have a Celtic mother and an Arab father, where the patient may be a Fitzpatrick type 1, 2, 3 or 4, are traditionally assessed and treated as the darker parent would have been regardless of their Fitzpatrick type. This is because of concern about the level of inflammation the peel may cause and the risk of post treatment pigmentation increasing.

However, there is good data to suggest this may not be the most appropriate course of action.

Nabil Fanous defined that facial features were more important than skin colour in determining PIH risk in mixed race clients. In simple terms, PIH risk is based on which parent the patient looked most like, skin colour supports the decision in choosing the correct protocol, but facial features take precedence in mixed race in determining PIH risk.[7]

For example, Celtic skin has high erythema sensitivity, whereas Arab skin has a high PIH risk. The offspring and patient with this mixed ethnic background may have the same Fitzpatrick skin type as a southern European; but the client would be treated differently, and the choice would be based on facial features not just Fitzpatrick type. If their features looked like the Celtic parent, then their PIH risk would be lower.

Ultimately, one size does not fit all. You need to ensure you do not cause long-term damage when treating the various skin types with peels, as you would with lasers.

Below is a useful table from the Fanous study.

RACIAL CATEGORIES	ORIGINAL GEOGRAPHIC HABITAT	CHARACTERISTICS OF SKIN AND FEATURES	COMPLICATIONS SIDE EFFECTS	CANDIDATE RATING FOR CLINICAL PROCEDURES
NORDICS (Swedish, Irish, etc)	Northern Europe	colour is light to very light. Skin and features are very fine	Erythema +++ Telangiectasia Scarring	Very good
EUROPEANS (French, Italian, English, Germans, etc)	Mid-Europe Southern Europe	Average colour and coarseness of skin and features	Low incidence	Excellent
MEDITERRANEANS (Spanish, Greek, etc)	Northern Africa and Western Asia	Darker and coarser than the Europeans	Hyper pigmentation + to ++ Erythema +	Very good
INDO-PAKISTANS (Pakistanis, Thais, etc)	Upper-Middle Africa and Lower Western Asia	Coarser and darker than the Mediterraneans with thick oily skin and hair	Hyper pigmentation +++ Hypo pigmentation +	Passable for Clinical Treatments
AFRICANS (Black Americans, Sudanese, etc)	Middle and Lower Africa	colour is black to deep black. Features and skin are coarse to very coarse	Hypo pigmentation +++ Hyper pigmentation ++	Passable for Clinical Treatments
ASIANS (Japanese, Koreans, etc)	Eastern Asia	A separate classification colour varies from light to medium dark. Skin and features are coarse to very coarse	Hyper pigmentation +++ Erythema +++ turning to hyper pigmentation	Good

PHOTOTYPE	DESCRIPTION
Phototype I	Subjects with very pale skin, often with freckles, blond or red hair, blue or grey eyes. They generally develop obvious erythema on any unprotected exposure to the sun. Tanning is very slight or nonexistent. There is extreme reaction to the sun's rays, with high risk of permanent damage.
Phototype II	Subjects with pale skin, dark blond or light brown hair. They tend to get sunburnt easily. They develop a light (golden) tan.
Phototype III	Subjects with fairly dark skin, brown hair. They only get sunburnt after prolonged exposure. They develop a deep, even tan.
Phototype IV	Subjects with olive complexion, dark eyes and black hair. They rarely get sunburnt. They quickly develop a very deep, chocolate-coloured tan.
Phototype V	Subjects with very dark complexion, dark eyes and black hair. They very rarely get sunburnt.
Phototype VI	Subjects with black complexion, dark eyes and black hair.

Fitzpatrick skin type

The Fitzpatrick classification categorises skin type according to its reactivity to the sun without UV protection rather than the degree of photo-damage. This classification helps identify patients who have a propensity for photo-damage. This relates to their likely risk level and response when exposed to skin challenging procedures.[11]

For facial chemical peels, this classification can also be used to define the risk of pigmentary changes (e.g., dyschromia, post inflammatory hyper pigmentation, permanent hypo pigmentation) and erythema when using resurfacing procedures.

Glogau scale

The Glogau scale of photo-ageing consists of four age-range levels where each level is defined by describing how a typical person's skin would appear in that age range and what visible symptoms, they would typically manifest.

Depending on the level of ageing, the depth and degree of treatment to the skin may need to be modified.

More challenging skin concerns would traditionally need more of the same agent and possibly for a longer exposure time; this would result in more trauma. An alternative approach is to expose the patient's skin to either a lower level of treatment and/or a shorter exposure time but to spread out the treatments over five to eight sessions instead of the usual four. So, it may be necessary to offer a different number of treatments, where the exposure time can be modified, and the results will become prominent over a longer time.

SCALE	AGE	DESCRIPTION
Slight	from 28 to 35 years	Characterized by small wrinkles, without keratosis
Moderate	from 35 to 50 years	Characterized by small wrinkles, sallow complexion with presence of actinic keratosis
Advanced	from 50 to 65 years	Characterized by deep wrinkles, presence of teleangiectasis, pigmented lesions and actinic keratosis
Severe	from 60 to 75 years	Characterized by dynamic and gravitational wrinkles, photo-ageing and actinic keratosis

Definitions
Keratosis – Increase of Keratin (thickening of skin)
Actinic – caused by solar radiation (can be pre malignant)
Telangiectasia - small dilated blood vessels near the surface of the skin
Pigmented lesions - A lesion is any abnormal tissue

Illustrations supplied by the author

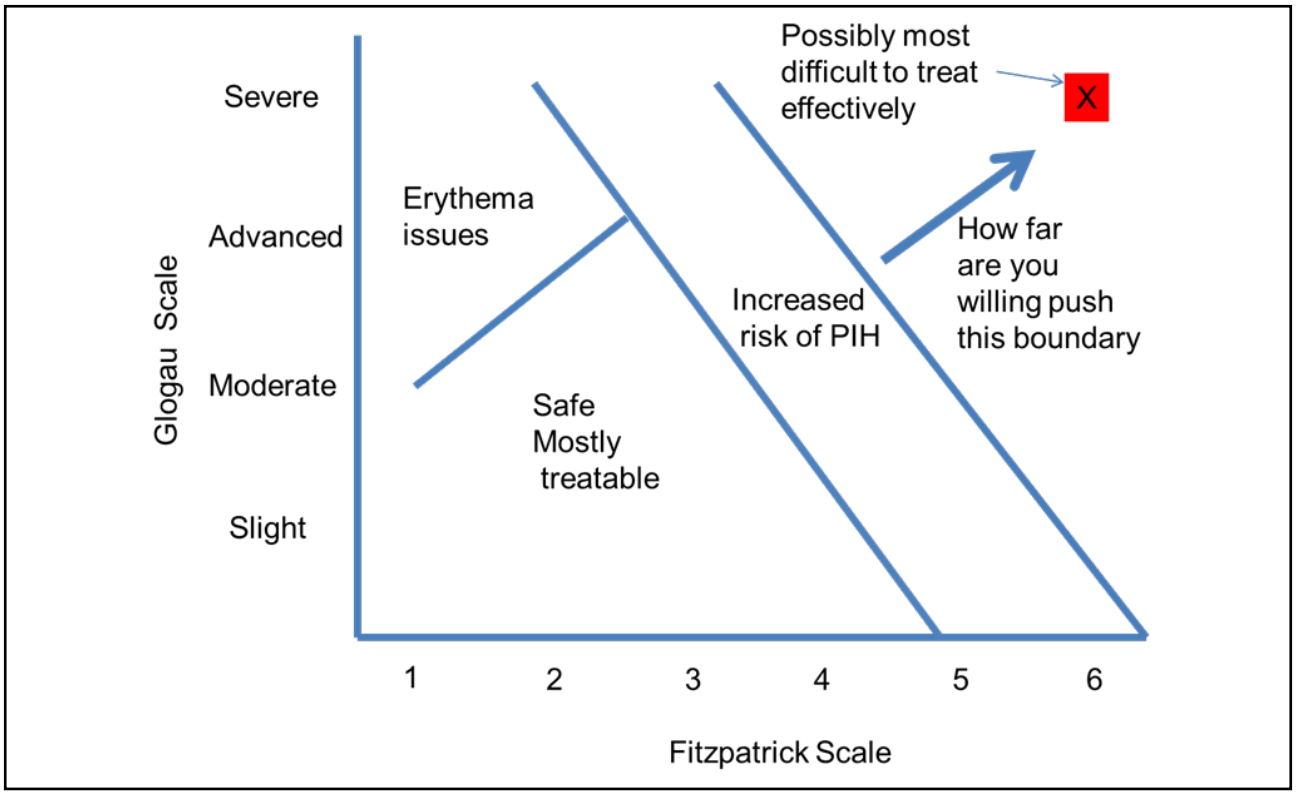

Above is a diagram that combines Glogau and Fitzpatrick skin type.

Importantconsiderations

- If patients present with a poor skin condition, such as low hydration, TEWL, pigmentation issues and damaged blood vessels, then consider no peel, but use creams for boosting skin structure, repair processes, priming and preparation, regardless of skin type. Then, an appropriate sequence of peels may be considered, interspersed with creams and serums to boost their response but also to limit complication development, such as pigmentation increase.

- Peels need water to move through the skin, therefore, skin with poor hydration is more likely to react to the acid component of the peel (hydrogen ions) and experience localised damage to the surface, is more irritating and more likely to lead to complications. This is because poor hydration causes less mobility for the hydrogen ions. (*Theoretical Chemistry/Acids and Bases/Aqueous Solutions/The Hydronium Ion – Chemistry*)

- The periorbital skin is much thinner than the rest of the face; hence this needs to be taken into consideration. The type of agent used can be similar, but the strength and surface activity need to be lower. Phenols and high strength TCAs or pyruvic acid would not be appropriate. In my opinion, it is better to use lighter concentrations and add more layers. The number of layers used would vary depending on the patient's skin type and sensitivity.

Length of peel time

Due to the ability to transport remodelling agents into the skin using specialised patented carrier technology[1, 2, 3, 4], this can reduce surface trauma normally seen with traditional peel solutions by up to 50%. Exposure time is set prior to application and the peel is neutralised or removed regardless of visible erythema or frosting.

However, the visible symptoms of the peel and patient response in terms of pain are still taken heed of, if trauma becomes apparent.

Exposure for mandelic is traditionally ten minutes, for pyruvic it is one to three and then if considered appropriate a second layer for up to a further two minutes, depending on layers and patient response, and for trichloroacetic acid (TCA) it is one to three minutes, before being neutralised. All other peels have varying exposure times.

Ideally, practitioners should use a neutraliser that can not only neutralise any surface acid, but also neutralise acid released in the skin.

Alkaline amino acids are useful as a neutraliser as they can be attached to the same carrier molecules as used with the acids; in other words, wherever the carrier has taken the acid in the skin, the neutraliser can follow and neutralise both on and in the skin.

Something like sodium bicarbonate is too big a molecule to carry into the skin and hence only neutralises on the surface.[12]

Mandelic usage has become more varied from a traditional ten-minute exposure and then neutralised, to also include now a partially extended or fully extended peel like a Jessner's, whereby the solutions are left active in the skin and only any remaining unabsorbed solution is removed at ten minutes. The mandelate attached to the carrier[1,2,3,4] is allowed to be released in the skin and convert to mandelic acid and is still active post the patient leaving the clinic, thereby extending the peels activity and boosting the results.